



**PRESENTING CLINICAL SIGNS**

**DATE** History: New grade 2 murmur. Pre-anesthetic evaluation.

**10/7/22 ECHOCARDIOGRAPHIC FINDINGS**

2D, M-mode, and Doppler study.

**PERFORMED BY:** Left atrial size is normal. The mitral valve is normal. Left ventricular wall thickness is normal. Left ventricular internal dimensions are normal. Left ventricular systolic function is hyperdynamic. The aorta and aortic valve are normal. Right atrial and right ventricular dimensions are normal. The tricuspid valve is normal. The pulmonary artery and pulmonic valve are normal. No shunting lesions are visualized. No pericardial effusion or cardiac masses are seen.

Kelly Vazquez

**INTERPRETED BY**

Keith Blass, DVM,  
MS, DACVIM  
(Cardiology)

**PATIENT**

Missy Liberti

LA/Ao - 1.20  
IVSd - 4.9 mm  
LVPWd - 4.6 mm  
LVIDd - 13.7 mm  
LVIDs - 6.1 mm  
FS - 55%  
LVOT - 1.11 m/s  
RVOT - 1.02 m/s

**ASSESSMENT/RECOMMENDATIONS**

Normal echocardiogram

**SPECIES**

Feline

This examination demonstrates no evidence of structural heart disease. While a definitive reason for Missy's murmur was not identified, it's likely that her murmur is functional/innocent in nature, as no flow abnormalities that could result in the development of a pathologic murmur were appreciated in the image set.

**BREED**

Norwegian Forest  
Cat

Missy's cardiovascular risk for general anesthesia is low based on this exam, and there are no contraindications to the use of any specific anesthetic agents.

No therapy is recommended based on this exam.

**SEX**

A recheck echocardiogram is recommended if the characteristics of Missy's murmur change, or if other new physical exam and/or clinical abnormalities suggestive of cardiac dysfunction develop.

FS

**AGE**

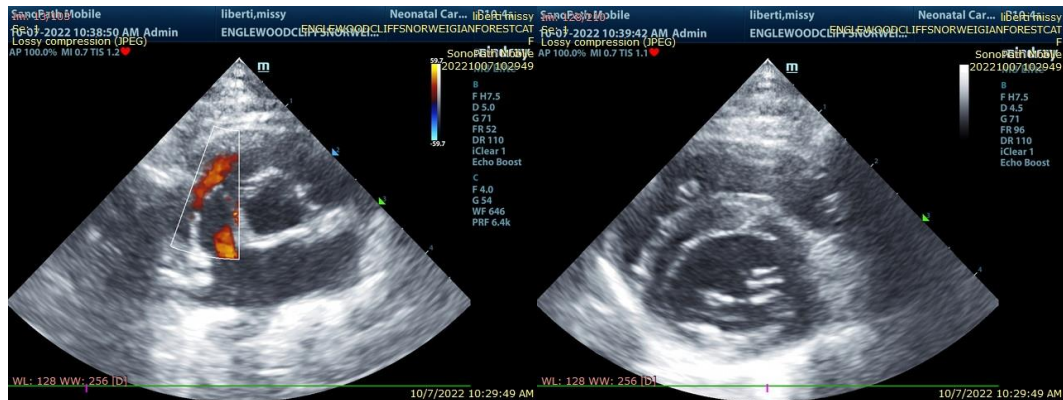
13 y

**WEIGHT**

7.9 lb

**HOSPITAL NAME**

Englewood Cliffs VH



**REFERRING VET**

The information and recommendations provided are based on the images presented by the

Dr. Attanasi/Park



**DATE** referring veterinarian. No evaluation can be communicated regarding pathology that was not visible in the image/video clips provided.

10/7/22 Thank you for this referral. If the clinical or image interpretation does not parallel your findings or if I can be of any further assistance please contact me.

**PERFORMED BY:** Keith Blass, DVM, MS, DACVIM (Cardiology)  
Kelly Vazquez KeithBlass@gmail.com  
631-804-5754

**INTERPRETED BY**

Keith Blass, DVM,  
MS, DACVIM  
(Cardiology)

**PATIENT**

Missy Liberti

**SPECIES**

Feline

**BREED**

Norwegian Forest  
Cat

**SEX**

FS

**AGE**

13 y

**WEIGHT**

7.9 lb

**HOSPITAL NAME**

Englewood Cliffs VH

**REFERRING VET**

Dr. Attanasi/Park